

TEETHMATE™ DESENSITIZER

CLINICAL CASE REPORT



CREATING HYDROXYAPATITE

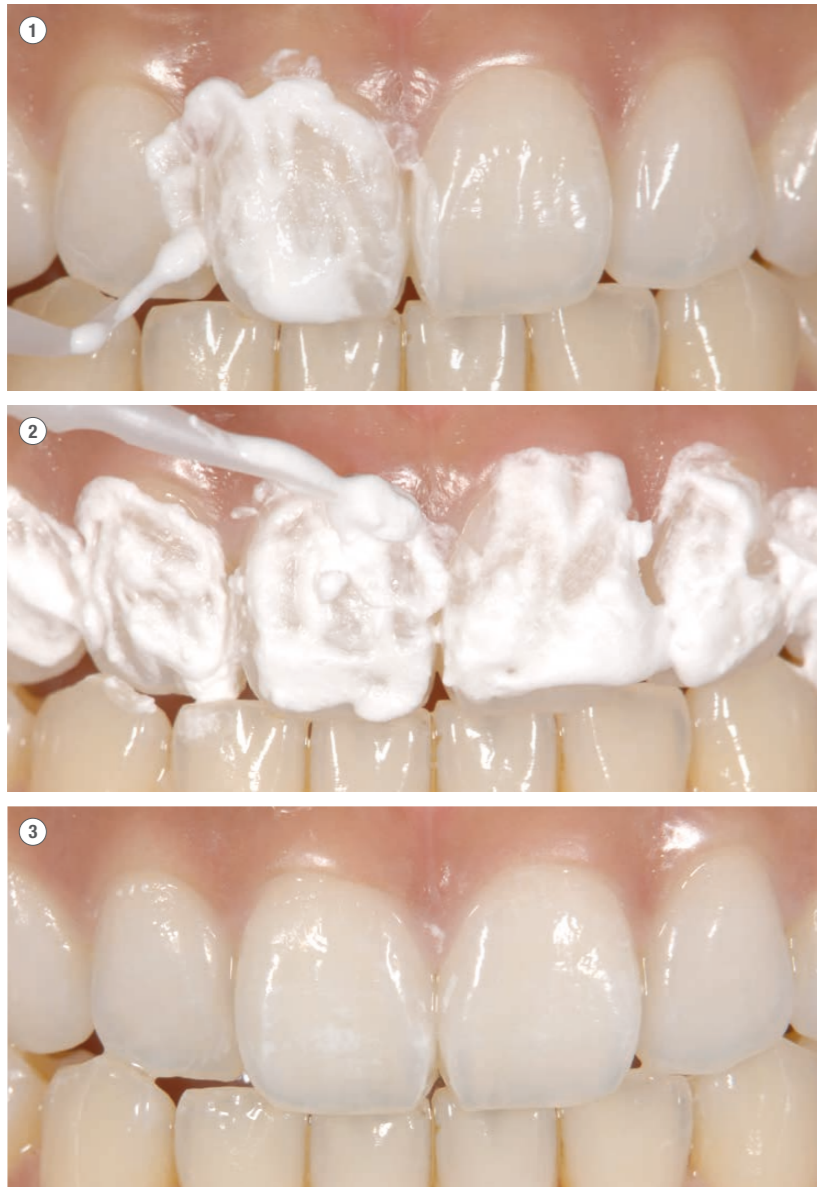
Dr. Kobayashi and Dr. Honda show you how to treat sensitive teeth effectively. And for the first time naturally, TEETHMATE™ DESENSITIZER creates hydroxyapatite to make such treatments effective.

They create hydroxyapatite exactly where it is needed. They use it to close exposed dentin tubules and enamel cracks. And they treat their patients' teeth after bleaching.

Let's see how Dr. Kobayashi and Dr. Honda treat dentinal hypersensitivity after bleaching, after gingival recessions and after scaling and root planing.

CASE 1: TEETH TREATMENT AFTER BLEACHING

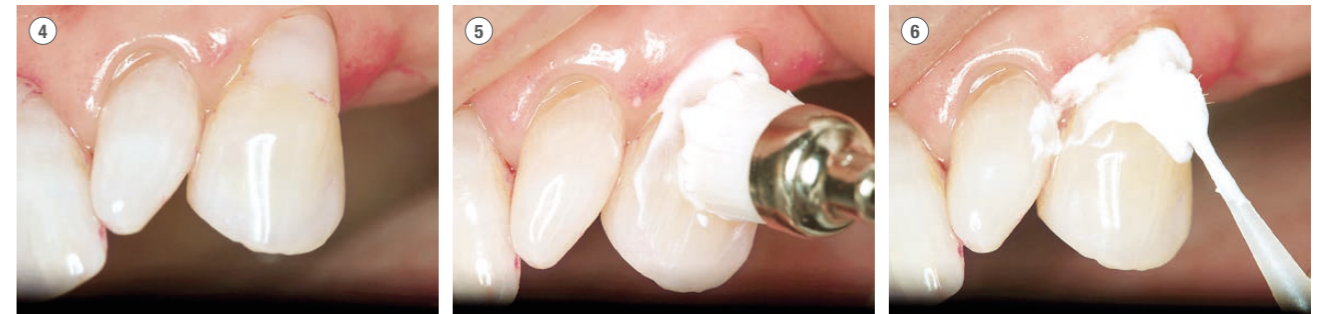- ① ② The pictures show the application of TEETHMATE™ DESENSITIZER on the upper front teeth after bleaching.
- ③ After the treatment you can see on the picture that TEETHMATE™ DESENSITIZER doesn't influence the esthetics.



Source: Dr. Ken Kobayashi, Japan

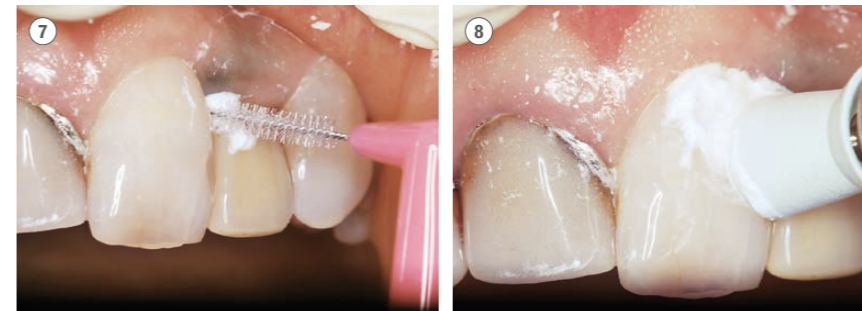
CASE 2: DENTIN TREATMENT AFTER GINGIVAL RECESSION

- ④ The patient has complained about sensitivity of tooth 23.
- ⑤ First, Dr. Honda cleans the tooth surface and the class V composite with a fine abrasive.
- ⑥ Then he rubs TEETHMATE™ DESENSITIZER on the sensitive area for 30 seconds and washes it away with water.



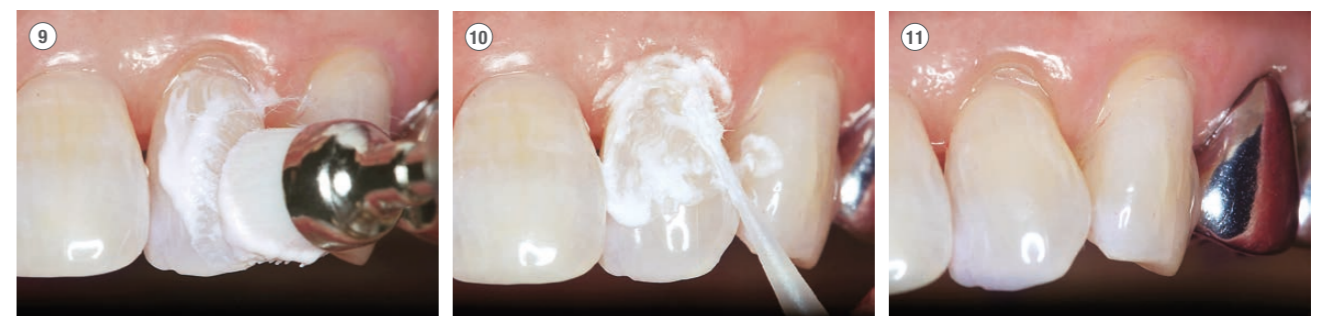CASE 3: DENTIN TREATMENT AFTER GINGIVAL RECESSION

- ⑦ Dr. Honda uses a commercially available interdental brush for a better application to the approximal areas.
- ⑧ It is good practice to use a rubber cup when applying TEETHMATE™ DESENSITIZER over a wide area.



CASE 4: DENTIN TREATMENT AFTER SCALING AND ROOT PLANING

- ⑨ The patient has complained about sensitivity of tooth 22. First Dr. Honda removes plaque and calculus using an air scaler. He uses a fine abrasive to clean the tooth surface.
- ⑩ He applies TEETHMATE™ DESENSITIZER to the tooth, rubs it in for 30 seconds and washes it away with water.
- ⑪ The TEETHMATE™ DESENSITIZER treatment shows an invisible result.



Source: Dr. Yuji Honda, Japan

TEETHMATE™ DESENSITIZER INDICATED FOR PREPARED DENTIN (ZIRCONIA, CAD/CAM)

An inlay was placed in the maxillary left second premolar using a CAD/CAM hybrid inlay (KATANA AVENCIA™ Block) and an abutment was reconstructed for the maxillary left first premolar using CLEARFIL™ DC CORE PLUS. After that, a zirconia crown (KATANA™ Zirconia ML) was put in place using PANAVIA™ V5 as an adhesive cement. The maxillary left second premolar's prepared dentin was conditioned using TEETHMATE™ DESENSITIZER. In the preparation of zirconia crowns, it is necessary to use caution to get improved adaptation by rounding the angles while avoiding creating knife-edge margins or J margins, in order to make smooth finishing lines. For the preparation of inlays, it is expected that the application of TEETHMATE™ DESENSITIZER will seal the dentinal tubules to avoid post-operative pain.

TEETHMATE™ DESENSITIZER consists of two different types of calcium phosphate (in powder form) as its main ingredients. When it is mixed with the LIQUID component, it forms hydroxyapatite (HAp), a main component of bone and teeth. Since TEETHMATE™ DESENSITIZER has the same ingredient as the tooth structure itself, it can be used without any worry about harmful effects if it comes in contact with the gingiva. TEETHMATE™ DESENSITIZER does not require either jets of air or light curing. Furthermore, there is no concern about having the restoration lift away, because no film is formed on the applied area. TEETHMATE™ DESENSITIZER also does not impair the polymerization of silicone impression materials. In addition, it does not impair the bonding action of resin cements. TEETHMATE™ DESENSITIZER, for application to prepared dentin, is a "must have" for our clinic. I believe that TEETHMATE™ DESENSITIZER will contribute greatly to the improvement of the satisfaction of patients.

CASE: TEETHMATE™ DESENSITIZER INDICATED FOR PREPARED DENTIN (ZIRCONIA, CAD/CAM)

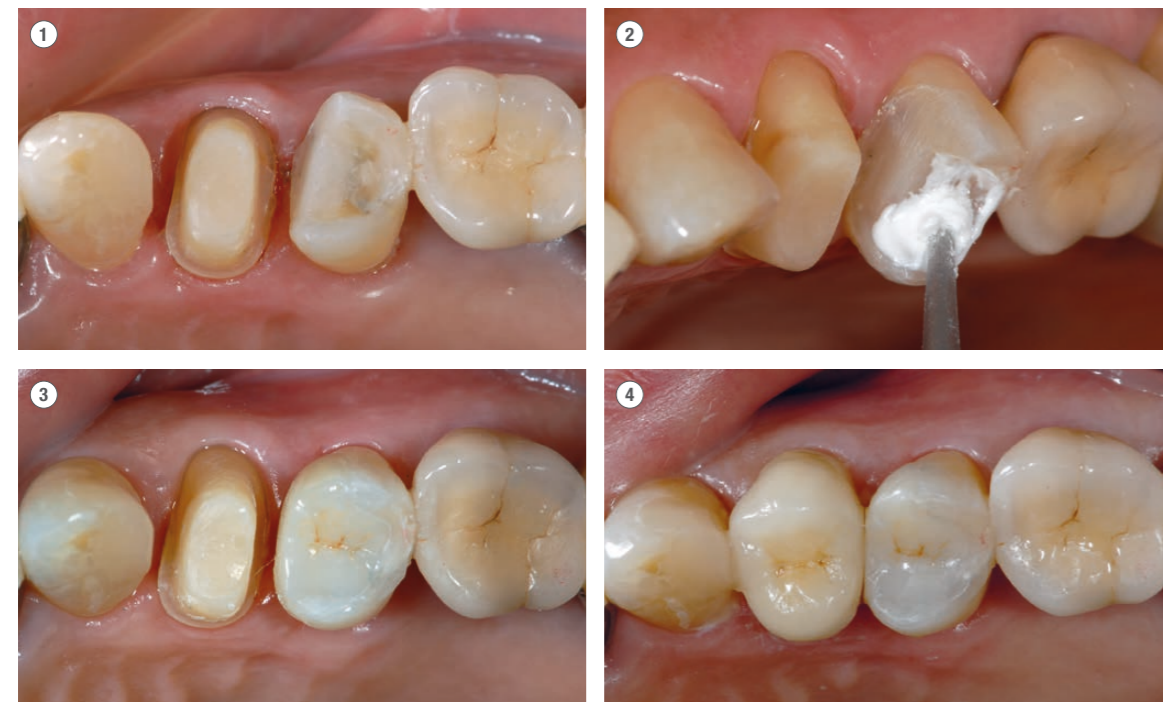- ① Upper left first premolar. An abutment was reconstructed using CLEARFIL™ DC CORE PLUS and a fiber post, followed by crown placement using KATANA™ Zirconia Block.
- ② Upper left second premolar. TEETHMATE™ DESENSITIZER was applied to seal the dentinal tubules cut immediately after cavity preparation.
- ③ Upper left second premolar. A CAD/CAM hybrid inlay was cemented to the tooth, using PANAVIA™ V5.
- ④ Then, a KATANA™ Zirconia crown was cemented to the upper left first premolar. using PANAVIA™ V5.



Dr. Masahiro Minami

Director of the Minami Dental Clinic in Osaka City

1986 Graduated from Osaka Dental University.
 1989 Worked for the Honda Dental Clinic in Higashi Osaka City and Kihara Dental Clinic in Ikoma City.
 1993 Opened the Mikkaichi Minami Dental Clinic in Kawachi-Nagano City, Osaka Prefecture.
 1998 Obtained his Doctoral degree in dentistry from Osaka Dental University.
 2003 Opened the Minami Dental Clinic in Kita-ku, Osaka City.
 2006 Established the Koryukai Minami Dental Clinic, a Medical Corporation.



Source: Dr. Masahiro Minami

TEETHMATE™ DESENSITIZER INDICATED FOR LOCAL HYPERSENSITIVITY CASES

There are quite a few patients who complain of getting a twinge in a tooth, or hypersensitivity, in our daily clinical setting. The cause of hypersensitivity is multifactorial, but in any event I believe that patients want to be relieved as soon as possible from such discomfort, which occurs every time they eat, drink or brush their teeth.

TEETHMATE™ DESENSITIZER does not need to be dried by jets of air and does not have an odor. It also does not damage the gingiva. By simply applying TEETHMATE™ DESENSITIZER slurry to the tooth structure and scrubbing it is possible to seal the dentinal tubules effectively and quickly, and the effect is longer lasting than expected. In cases where pain is felt locally or gingival recession is observed, we make it a point of applying TEETHMATE™ DESENSITIZER slurry using the attached applicator brush to avoid excessive stimulation (as may occur if we use a rubber cup).



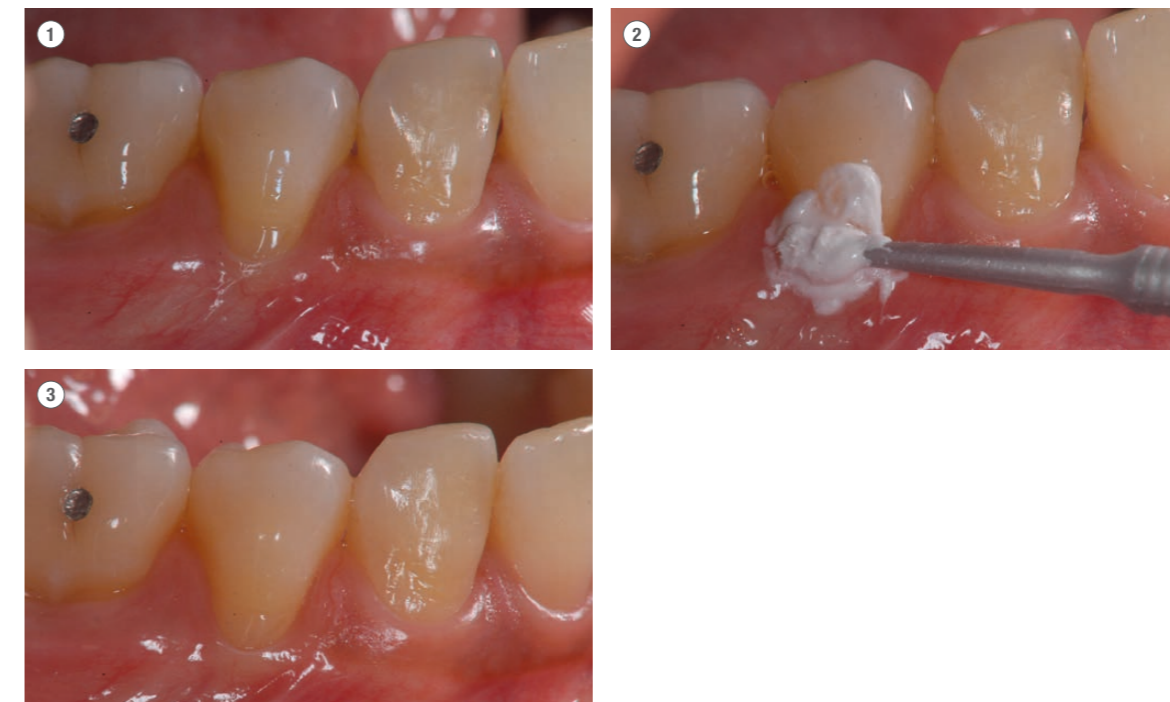
Sawako Kishima

Dental Hygienist, Minami Dental Clinic in Osaka City

1984 Graduated from Osaka Dental Institute College.
 1984 - 2003 Worked for the Honda Dental Clinic in Higashi Osaka City
 2003 - Worked for the Koryukai Minami Dental Clinic, a Medical Corporation.

CASE: TEETHMATE™ DESENSITIZER INDICATED FOR LOCAL HYPERSENSITIVITY CASES

- ① Hypersensitivity was reported in the lower right canine..
- ② TEETHMATE™ DESENSITIZER was applied, then scrubbed, using the applicator brush.
- ③ The TEETHMATE™ DESENSITIZER was easily washed away with water.



Source: Sawako Kishima

TEETHMATE™ DESENSITIZER INDICATED FOR PREPARED DENTIN (A PORCELAIN INLAY)

In this case there was a fractured porcelain restoration on a mandibular premolar. Judging from the appearance of the infected dentin in the bottom of the cavity, it was highly likely that the resin cement layer had sustained an adhesive failure prior to the fracture of the inlay body. The infected dentin was removed and the cavity was prepared for the placement of a new porcelain inlay. After that, in order to protect the opening of the dentinal tubules and suppress hypersensitivity, TEETHMATE™ DESENSITIZER was applied to the surface of the dentin inside the cavity. The application of TEETHMATE™ DESENSITIZER was performed after the preparation of the cavity was completed and before the completed porcelain inlay was inserted in place. It was then confirmed that hypersensitivity did not develop during the temporary sealing period or immediately after the completion of the restoration. TEETHMATE™ DESENSITIZER does not impair the film thickness or the bond strength of adhesive resin cements, if it is applied inside the cavity immediately before the placement of the porcelain inlay. In this case, the restoration was completed satisfactorily with good color matching, using a new type of resin cement (PANAVIA™ V5 shade: Universal).



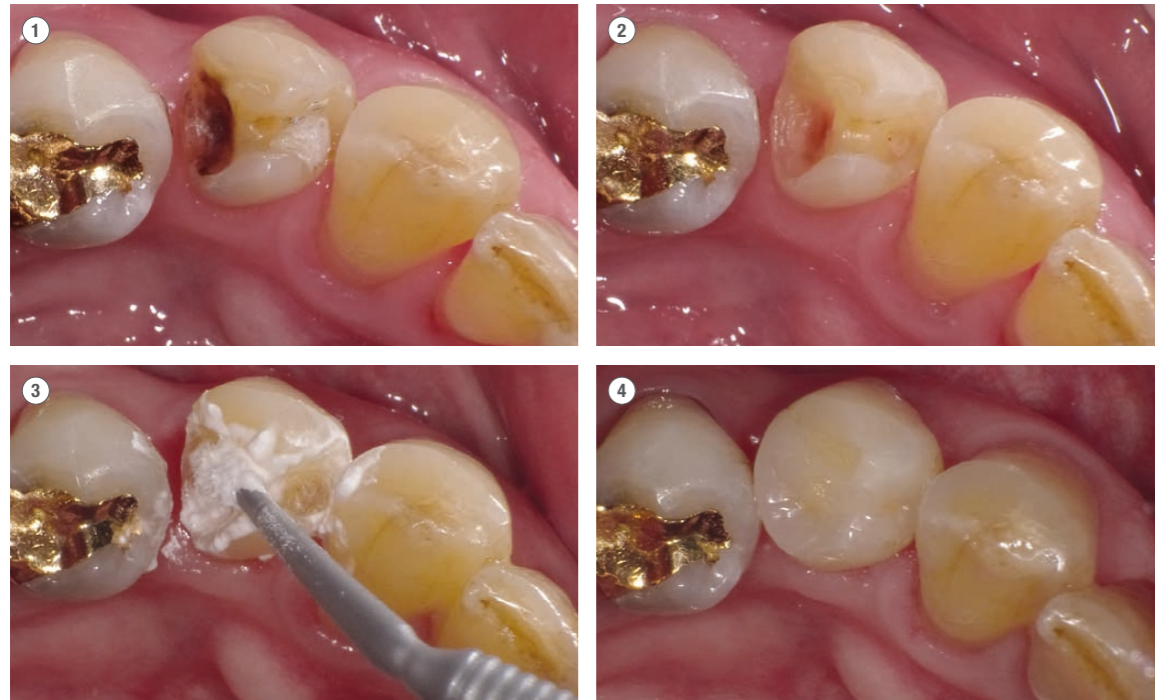
Dr. Hiroshi Tashiro

Director of Tashiro Dental Clinic in Hamamatsu City, Shizuoka Prefecture

1999 Graduated from Tokyo Medical and Dental University, School of Dentistry.
 2000 Worked as an instructor in Operative Dentistry at DES Dental Educational School.
 2003 Completed his Master's degree at Tokyo Medical and Dental University.
 Obtained his Doctoral degree through research into dental high-performance adhesives from Tokyo Medical and Dental University.
 2003 Opened the Tashiro Dental Clinic in Hamamatsu City, Shizuoka Prefecture, Japan.
 2007 Part-time instructor (in the study of caries control) at Tokyo Medical and Dental University.

CASE 1: TEETHMATE™ DESENSITIZER INDICATED FOR PREPARED DENTIN (A PORCELAIN INLAY)

- ① Before treatment. Fractured porcelain inlay and secondary caries.
- ② Cavity preparation completed.
- ③ Application of TEETHMATE™ DESENSITIZER to dentin inside cavity.
- ④ After treatment. Placement of porcelain inlay completed.



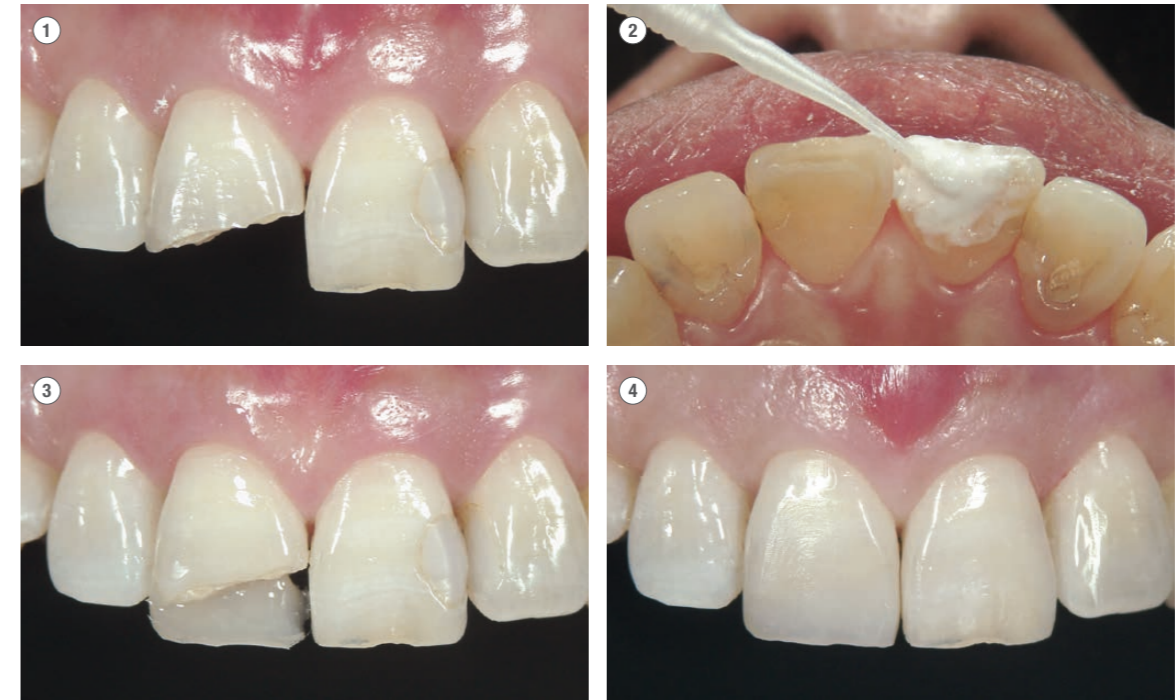
Source: Dr. Hiroshi Tashiro

TEETHMATE™ DESENSITIZER INDICATED FOR A FRACTURED CROWN

In cases where the crown tooth structure is badly fractured, the open ends of the large diameter dentinal tubules are often exposed at the fractures, increasing the risk of bacterial infection of the pulp. Therefore, it is necessary to resolve the situation of the indirectly exposed pulp by covering the open ends of the dentinal tubules at the fracture sites as soon as possible, using a composite resin restoration. However, it is likely that the fractured sections of deep dentin that need to be covered will not accept the bond with the composite resin due to the seepage of fluid into the dentinal tubules. In such a case, it is expected that the application of TEETHMATE™ DESENSITIZER onto the fractured sections will result in the formation of hydroxyapatite crystals in the ends of the dentinal tubules, suppressing the transmission of stimulants and seepage of fluid into the dentinal tubules. In addition, the forming of hydroxyapatite crystals in the dentinal tubules does not impair the penetration or the bond strength to dentin of the bonding agents used for the composite resin restoration.

CASE 2: TEETHMATE™ DESENSITIZER INDICATED FOR A FRACTURED CROWN

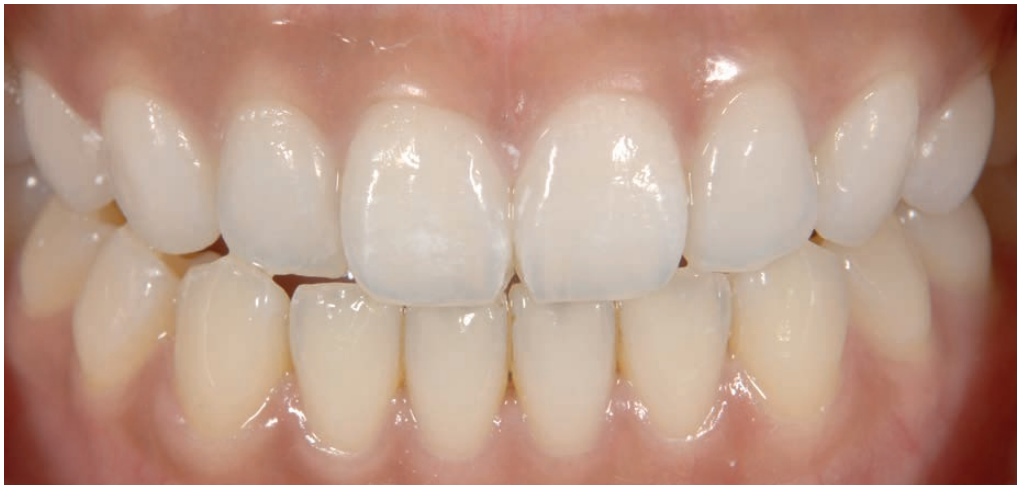- ① Before treatment. Large-scale fractures of the crown tooth structure.
- ② Application of TEETHMATE™ DESENSITIZER to the fractured sections.
- ③ Layering of composite resin on the fractured areas.
- ④ After treatment. No pulp-related symptoms developed.



Source: Dr. Hiroshi Tashiro

HAPPY WITH THEIR TEETH AGAIN

As you can see, rinsing TEETHMATE™ DESENSITIZER with water from the tooth surface and gingiva shows great results. Your patients will love the neutral taste and the result. And most of all - your patients will be happy with their teeth again.



Source: Dr. Ken Kobayashi, Japan

YOUR CONTACT

Kuraray Europe GmbH

BU Medical Products
Philipp-Reis-Strasse 4

65795 Hattersheim am Main
Deutschland

Website www.kuraraynoritake.eu

Phone +49 (0)69 305 35 835

E-Mail centralmarketing@kuraray.com

- Before using this product, be sure to read the Instructions for Use supplied with the product.
- The specifications and appearance of the product are subject to change without notice.
- Printed color can be slightly different from actual color.

"TEETHMATE", "CLEARFIL", "AVENCIA" and "PANAVIA" are trademarks of Kuraray Co., Ltd.
"KATANA" is a trademark of NORITAKE CO., LIMITED.



Kuraray Noritake Dental Inc.

1621 Sakazu, Kurashiki, Okayama 710-0801, Japan
Website www.kuraraynoritake.com

